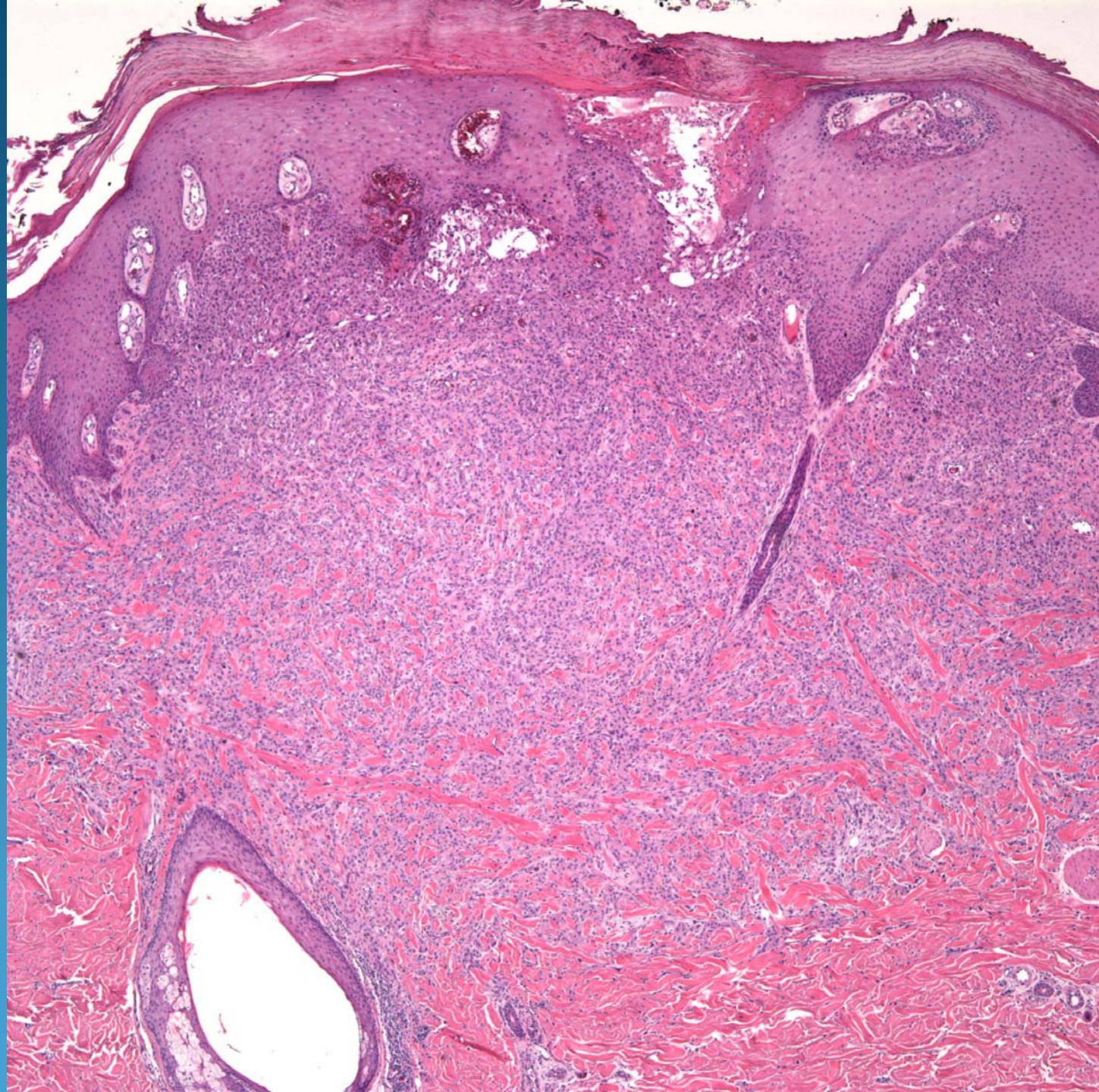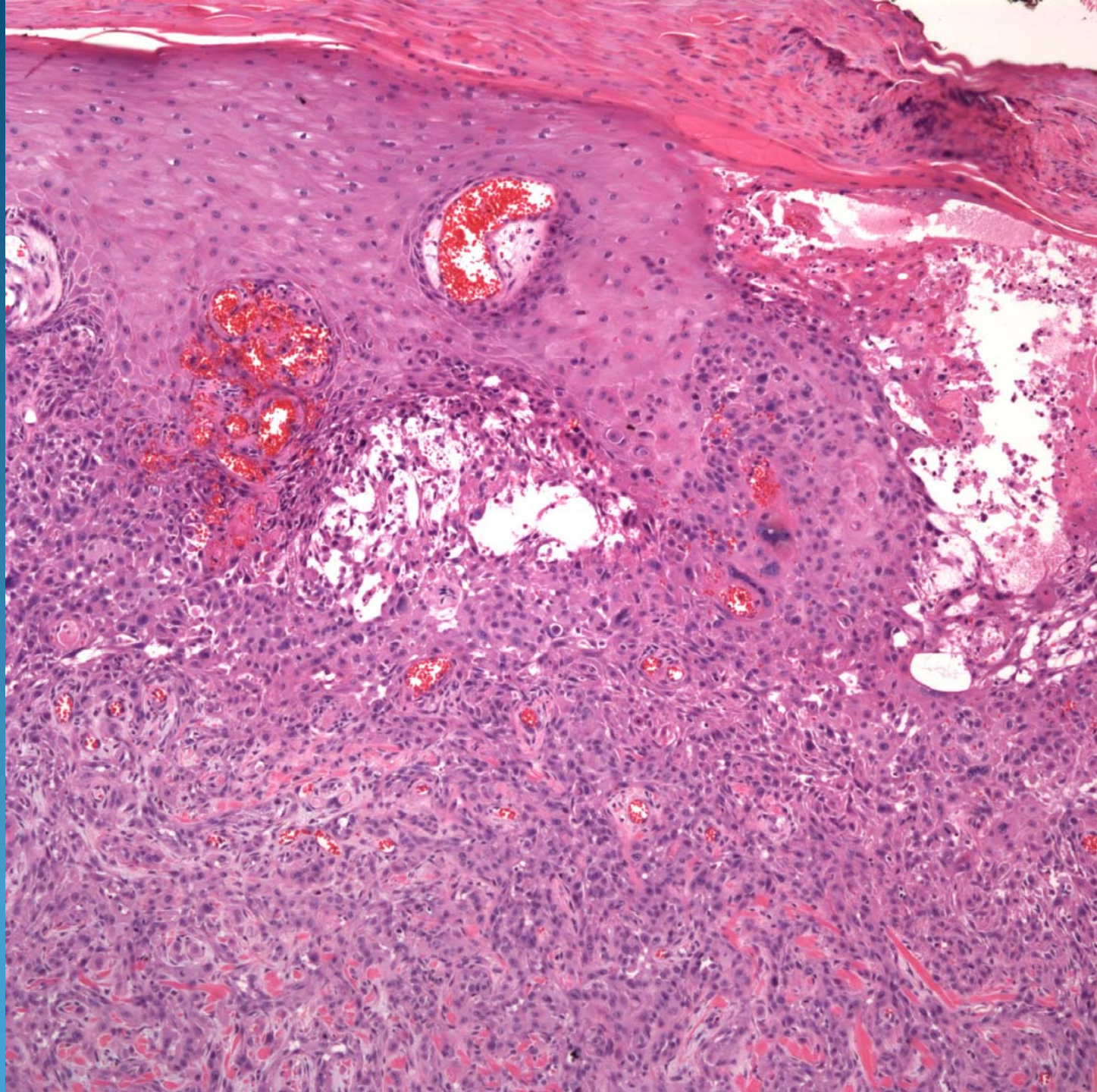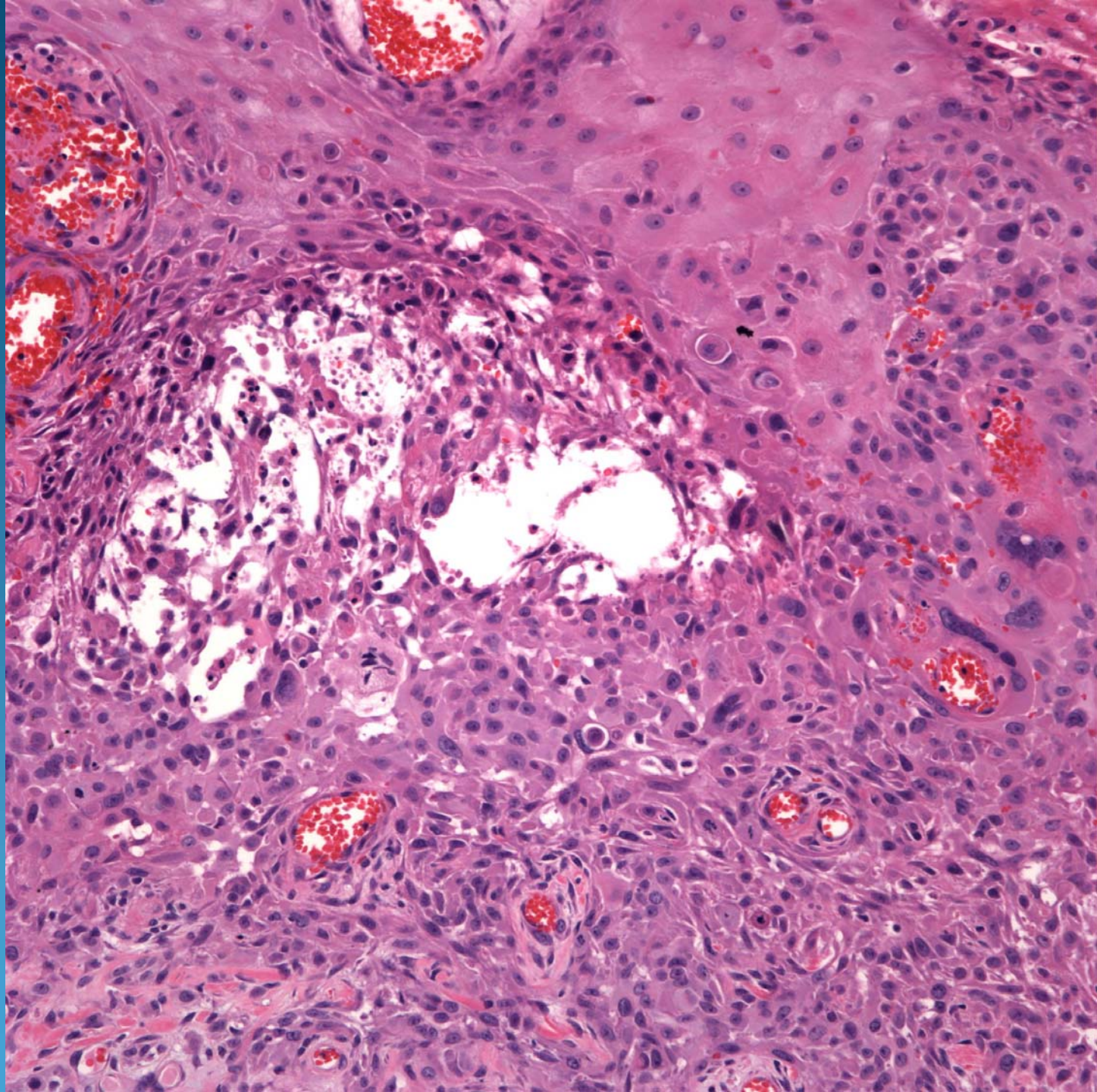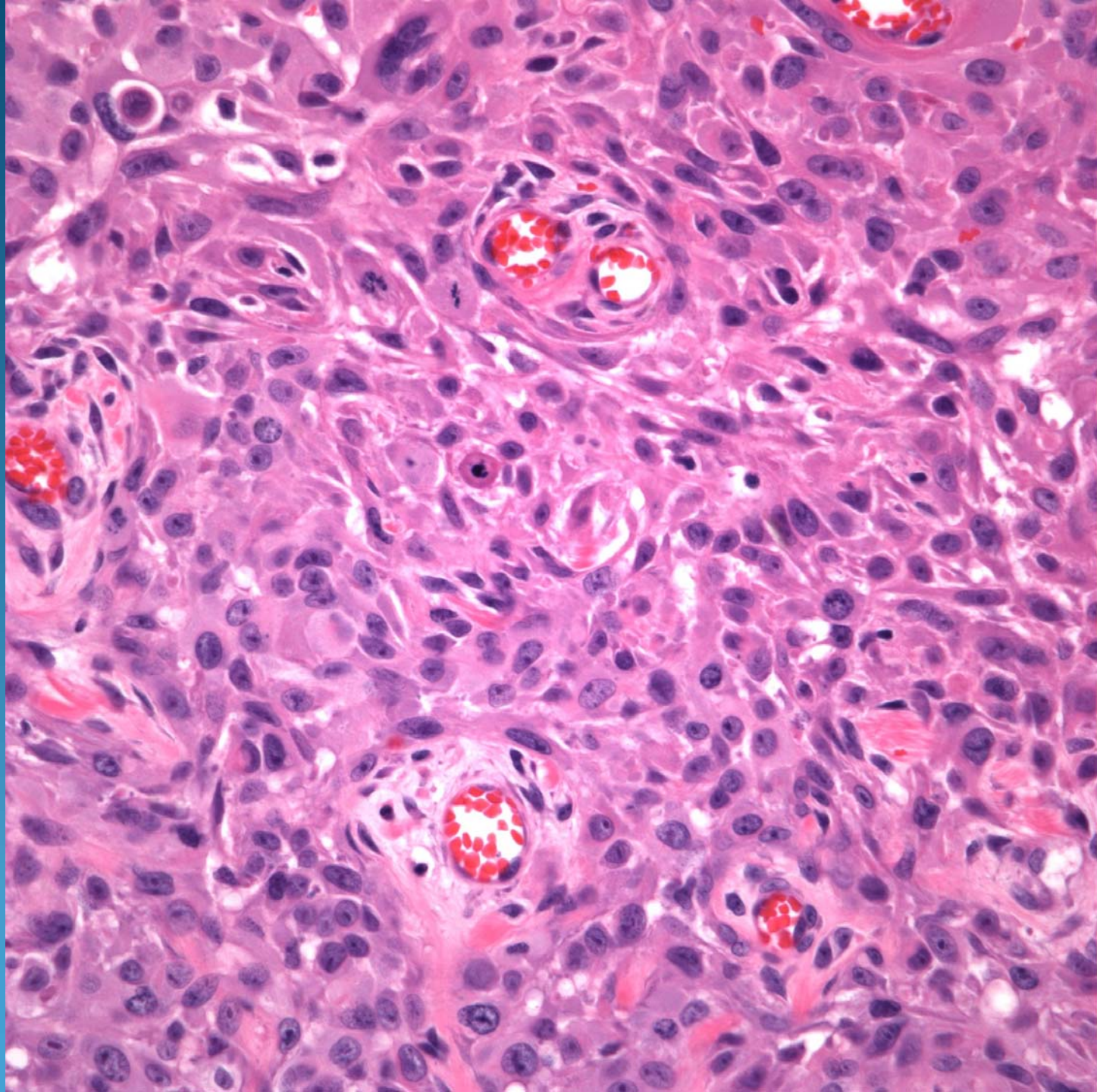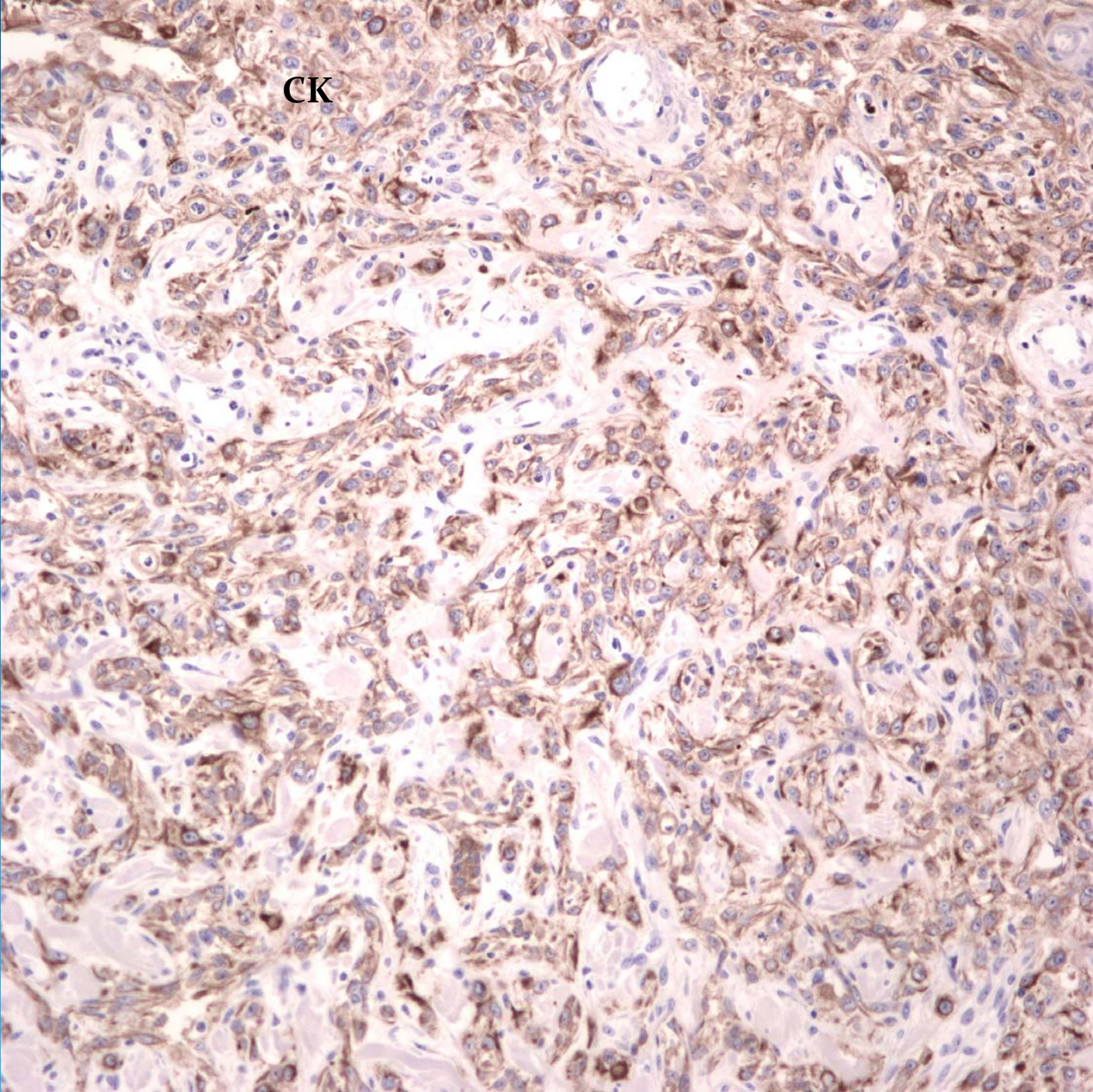
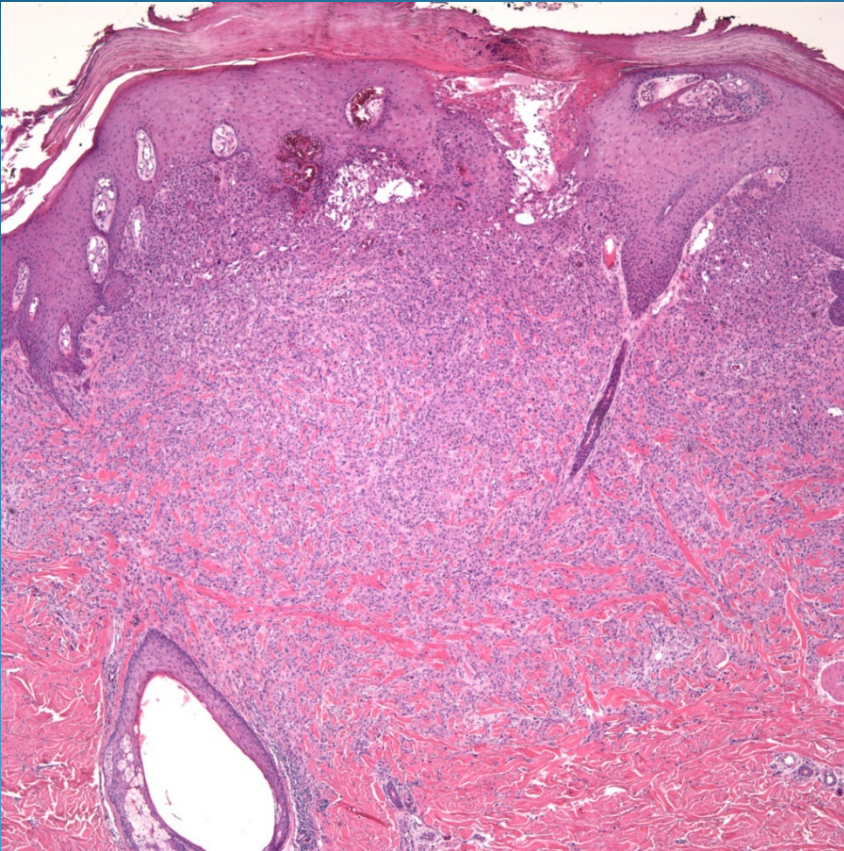


CK



Invasive Squamous Cell Carcinoma, Poorly Differentiated

Pearls



- Diffuse sheets of pleomorphic cells
- Look for epidermal attachment
- May show focal keratinization and intercellular bridges
- May need IHC for CK to confirm